

Endoscopic submucosal dissection in the West: difficult but not impossible

Stefanos P. Bassioukas

Saint Savvas Oncological Hospital of Athens, Athens, Greece

The detection rate of early gastric cancer (EGC) in the West constitutes 10% of endoscopically diagnosed gastric carcinoma cases. In contrast, Japanese endoscopists recognize 50% of gastric cancer at an early stage [1]. In these cases, endoscopic submucosal dissection (ESD) technique is considered as the first option for accurate histopathological assessment and alternative therapy to surgery if certain criteria are fulfilled [2]. However, in the West the technically demanding nature of ESD and the relatively low frequency of diagnosed EGC have limited the use of this technique in a few tertiary centers.

In our hospital, a 64-year-old man was referred with a diagnosis of a 0-IIa 4.5 cm intramucosal cancer at the posterior wall of the lower part of the gastric body (Fig. 1A). CT-scan and EUS staging revealed no lymph node involvement. Unfortunately, the patient presented a heart attack episode a few days later. He successfully underwent urgent placement of 5 drug-eluting coronary stents with concomitant clopidogrel and aspirin anticoagulant medication. Six months later, he discontinued clopidogrel and underwent ESD of the lesion, as an expanded criteria case, under aspirin use [3]. The procedure was deemed as technically demanding due to the impossibility of an endoscopic retroflexed approach and the size of the lesion. In addition, diffuse fibrosis of the submucosal layer hampered the ease of dissection. IT-2 Knife and Hook-Knife (Olympus, Tokyo, Japan) were mainly used (Fig. 1B). Procedural time exceeded 6 h. The histology of the *en bloc* dissected specimen revealed a well differentiated intramucosal-type cancer with negative vertical and horizontal margins with no lymphovascular infiltration (Fig. 1C).

Acknowledgement

Dr. Satoshi Tanabe (Kitasato University East Hospital, Sagami-hara, Kanagawa, Japan) for ESD training and case consultation

Gastroenterology Clinic, Department of Interventional Endoscopy, "Saint Savvas" Oncological Hospital of Athens, Greece

Conflict of Interest: None

Correspondence to: Stefanos P. Bassioukas, Alexandras Avenue 171, Athens, Greece, 11522, Tel: +30 210 6409407, Fax: +30 210 6409409, e-mail: sbassioukas@gmail.com

Received 27 July 2013; accepted 8 August 2013

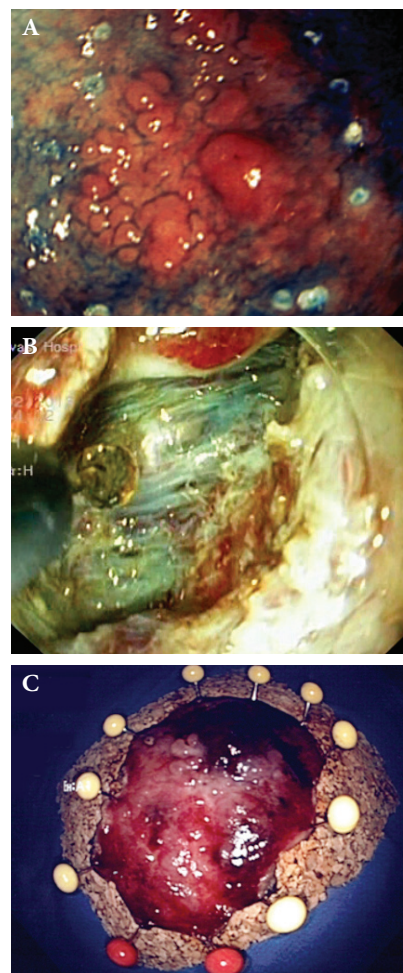


Figure 1 (A) Marking of the lesion after Indigo Carmine chromoendoscopy. (B) Dissection of the submucosal layer with the aid of IT-2 knife. (C) The dissected specimen, orange needles indicate the oral side

References

1. Coda S, Lee SY, Gotoda T. Endoscopic mucosal resection and endoscopic submucosal dissection as treatments for early gastrointestinal cancers in Western Countries. *Gut Liver* 2007;1:12-21.
2. Uedo N, Takeuchi Y, Ishihara R. Endoscopic management of early gastric cancer: endoscopic mucosal resection or endoscopic submucosal dissection: data from a Japanese high-volume center and literature review. *Ann Gastroenterol* 2012;25:281-290.
3. Boustière C, Veitch A, Vanbiervliet G, et al. Endoscopy and antiplatelet agents. European Society of Gastrointestinal Endoscopy (ESGE) Guideline. *Endoscopy* 2011;43:445-461.